

A PRESUMED DYSONTOGENETIC ORBITAL CYST IN A DOG

Ingrid Allgoewer¹, Sabine Sahr¹, Michael Burger², Achim D. Gruber³

[1] Animal Eye Practise, Berlin, Germany, praxis@tieraugen.com



[2] Practise for Small Animal Surgery Dreilinden, Berlin, Germany, info@kleintierchirurgie-dreilinden.de

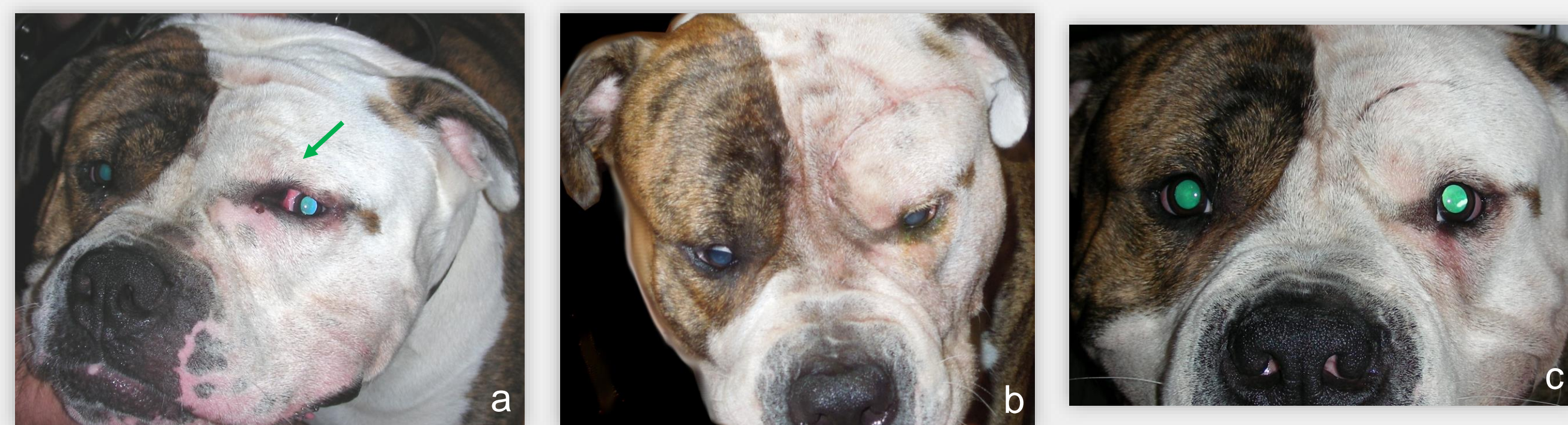


[3] Institute of Veterinary Pathology, University of Berlin, Germany, achim.gruber@fu-berlin.de



Case

- ❖ 1- year-old male American Bulldog with a progressive swelling of the nasal aspect of the left eye of 4 months' duration
- ❖ Clinical examination
 - elastic swelling of the left nasal canthus area with orbital involvement
 - obstructed nasolacrimal duct
- ❖ Fine needle aspiration
 - 20 ml of an opaque brown fluid, non-diagnostic cytologic findings, negative culture
- ❖ Sclerotherapy
 - repeated injections of the sclerosing agent polidocanol (Aethoxysclerol®) into the cyst were not effective
- ❖ Surgery
 - transfrontal orbitotomy 6 months after initial presentation
 - removal of the entire cystic structure
 - recovery uneventful
 - postoperatively unimpaired eye movements and vision
 - left nasolacrimal drainage system continued to be obstructed
 - no recurrence of the cystic structure 7 months after surgery



Photographs of the patient 'Hank'. (a) before surgery, (b) 3 weeks after surgery, (c) 7 months after surgery

Definitions

- Dysontogenesis** defective embryonic development
- Primary cyst** no communication with surface epithelium, sinuses, nasal cavity, brain...
- Secondary cyst** extending into the orbit from adjacent structures

Orbital cysts in human medicine

- ❖ Cysts of surface epithelium
 - simple epithelial cyst (without adnexal structures)
 - epidermal, conjunctival, respiratory, apocrine gland
 - developmental/ after surgical or nonsurgical trauma
 - dermoid cyst (contains adnexal structures)
 - (epidermal and conjunctival)
- ❖ Teratomatous cysts, neural cysts, secondary cysts (e.g. mucocele), inflammatory cysts (parasitic cysts)

Veterinary medicine (no consistent classification)

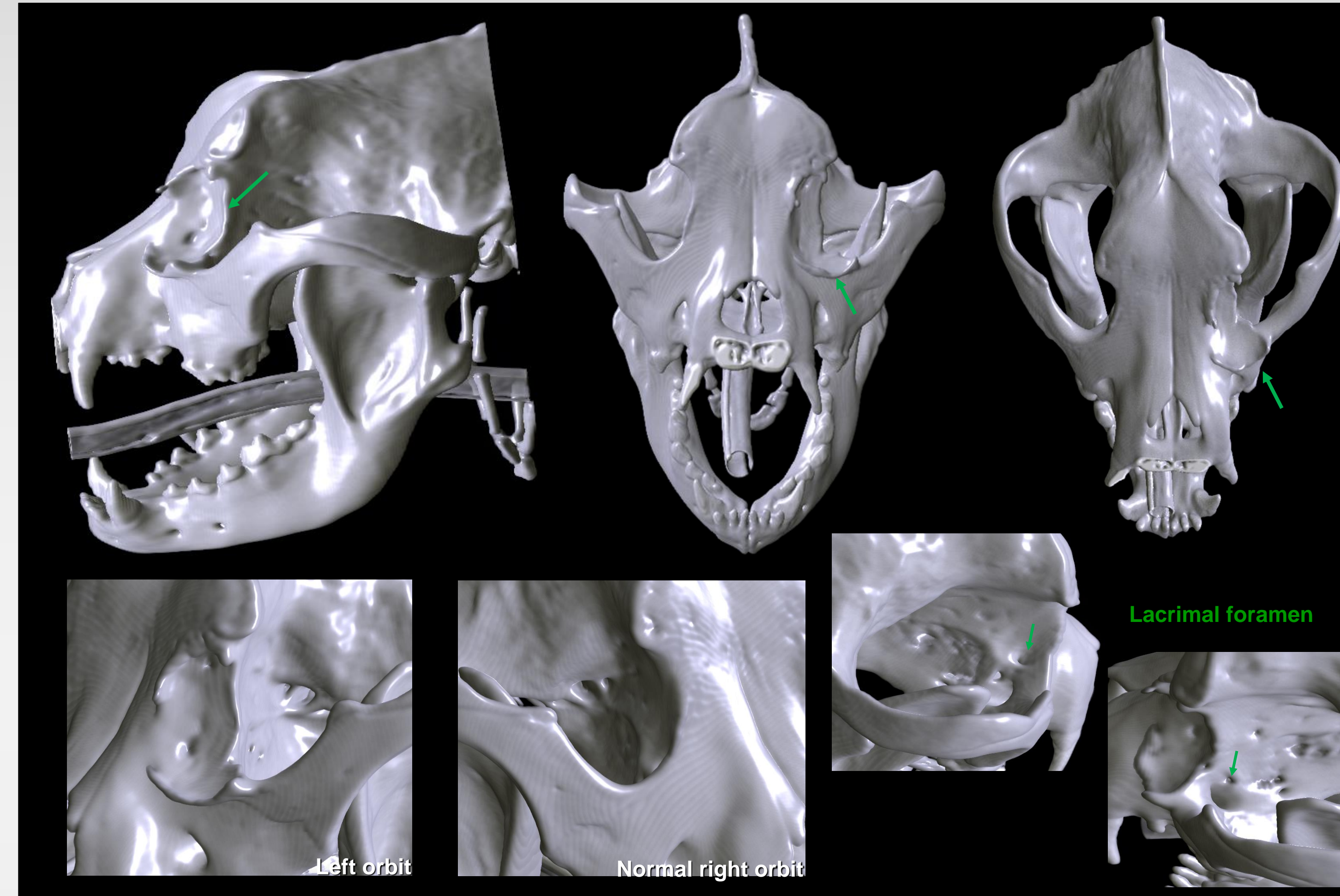
- Dacryops (cyst of lacrimal sac, cyst of lacrimal gland)
- Paraorbital (epithelial) cysts, Neural cysts, Dermoid cyst (horse, dog)
- Zygomatic and lacrimal mucoceles
- Cysts as a result of surgical or non surgical trauma
- Inflammatory cysts (parasitic cysts in a rabbit, a chinchilla and an ewe)

Purpose

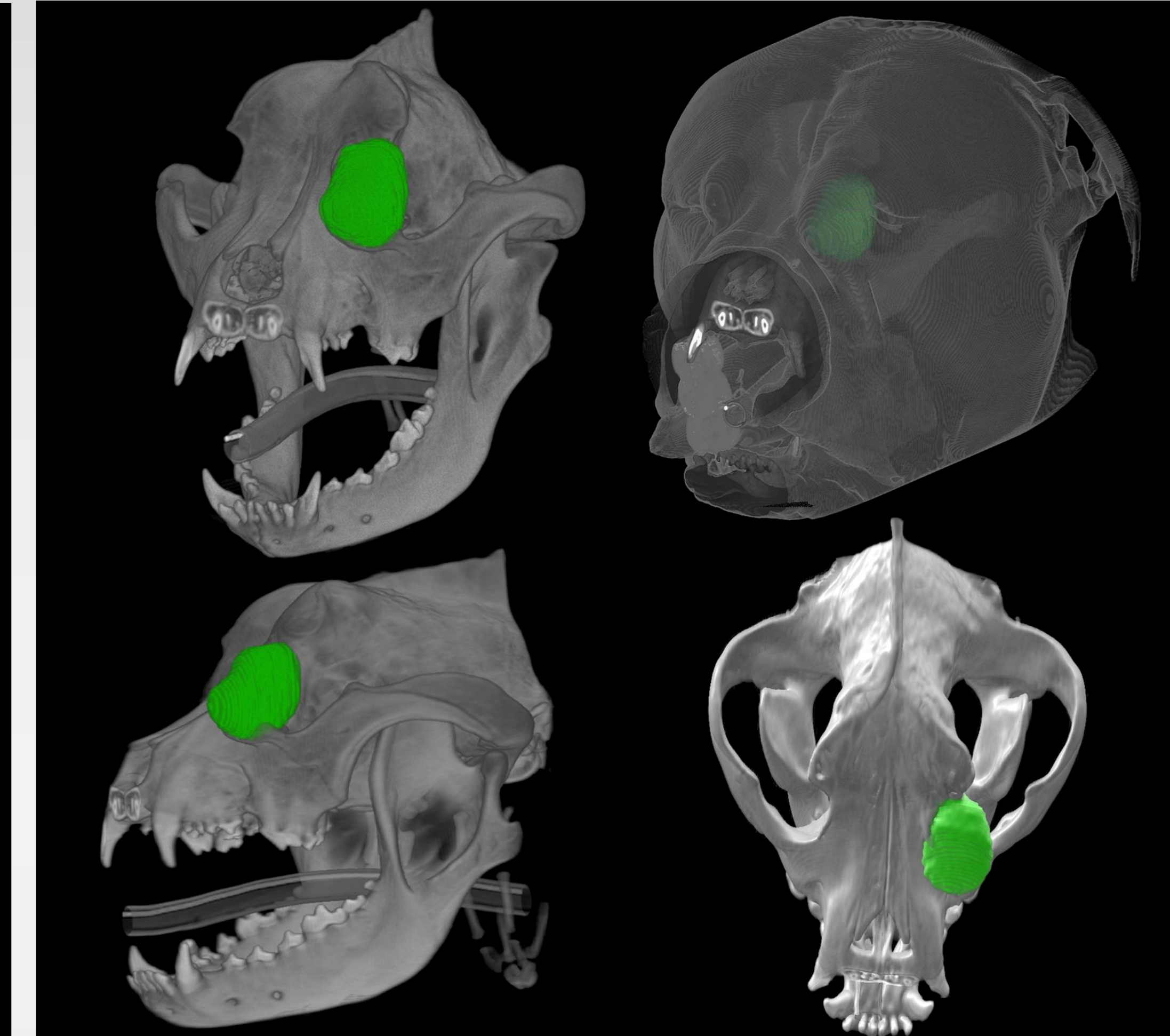
We describe the clinical, histopathological features and the treatment of a dysontogenetic orbital cyst in an American Bulldog.

Computed tomography and 3D – Reconstruction

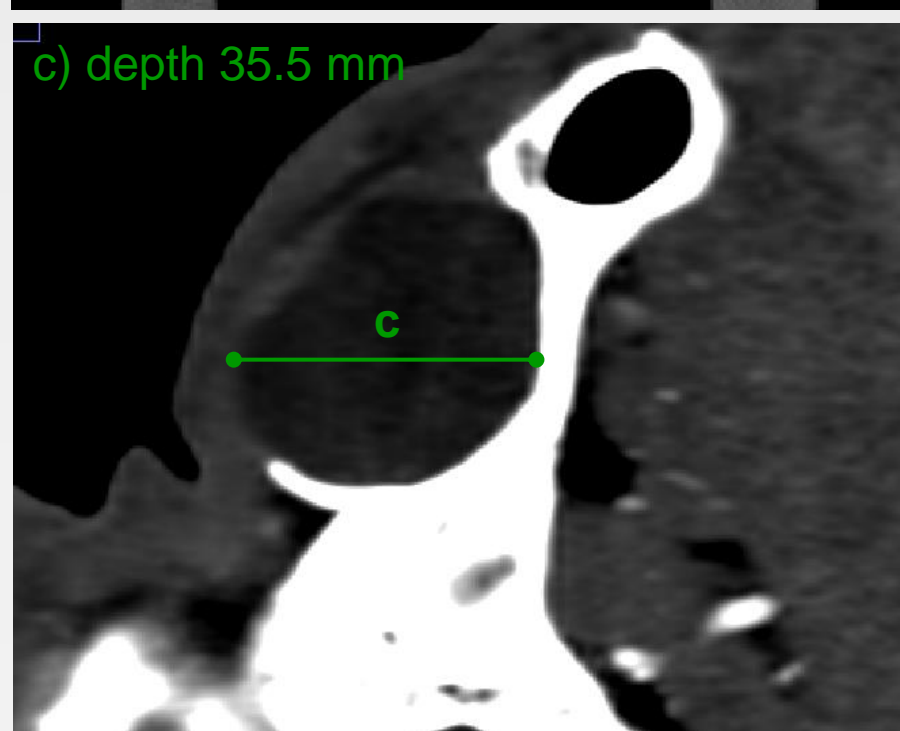
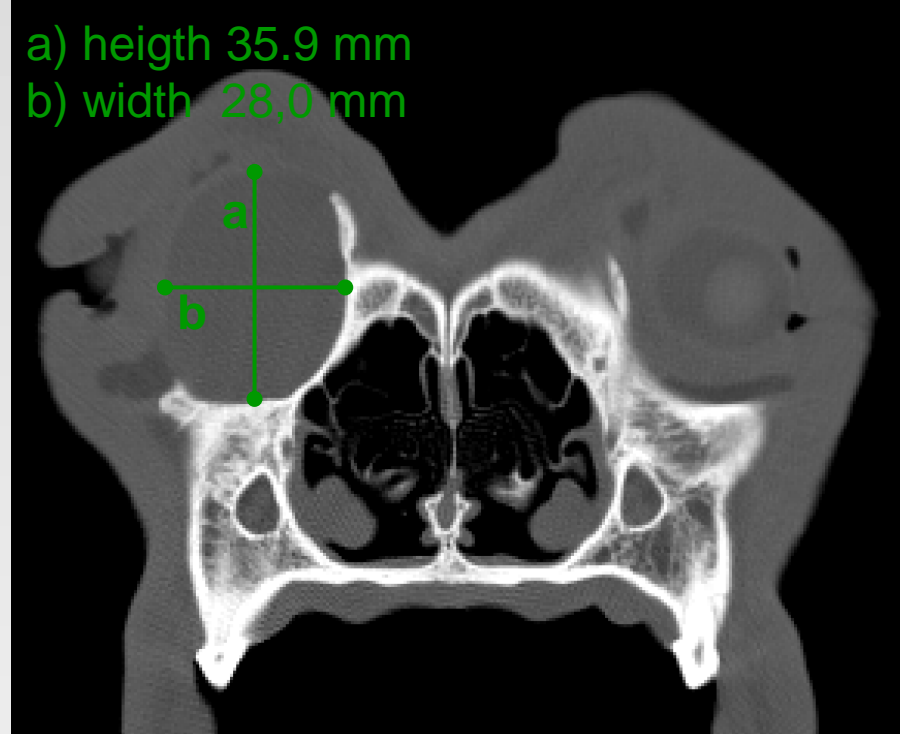- ❖ large orbital cyst with thinning of the adjacent bony structures, periosteal reaction and deformation of lacrimal bone, orbit and maxillary bone



3D-illustration of the skull (Volume Viewer ImageJ); The left orbit exhibits marked cyst-induced osseous changes of its anterior aspect

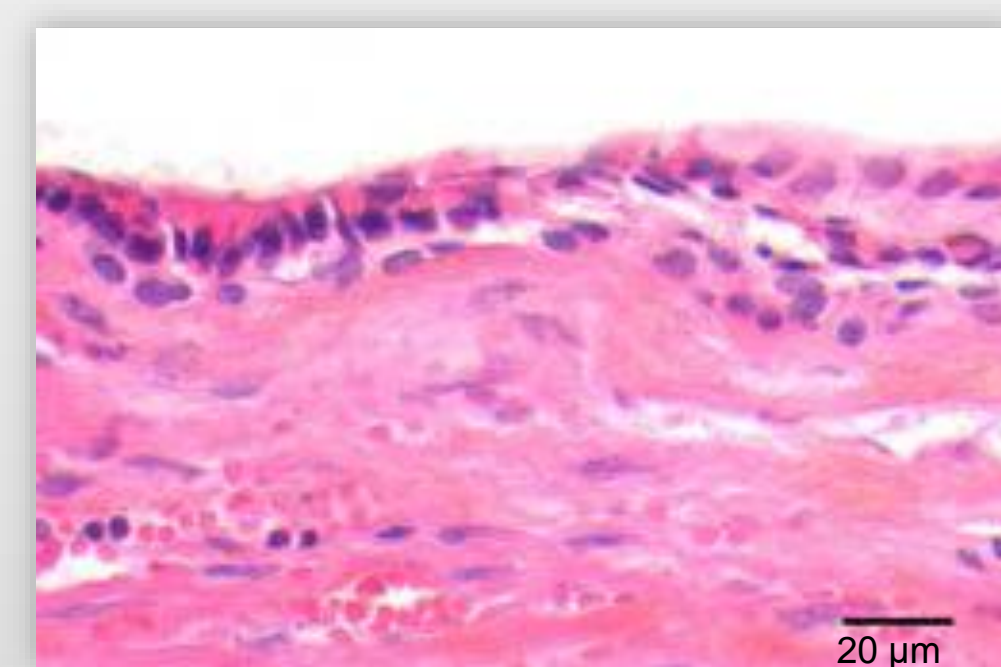


3D-illustration of the cyst after manual segmentation (Volume Viewer ImageJ)

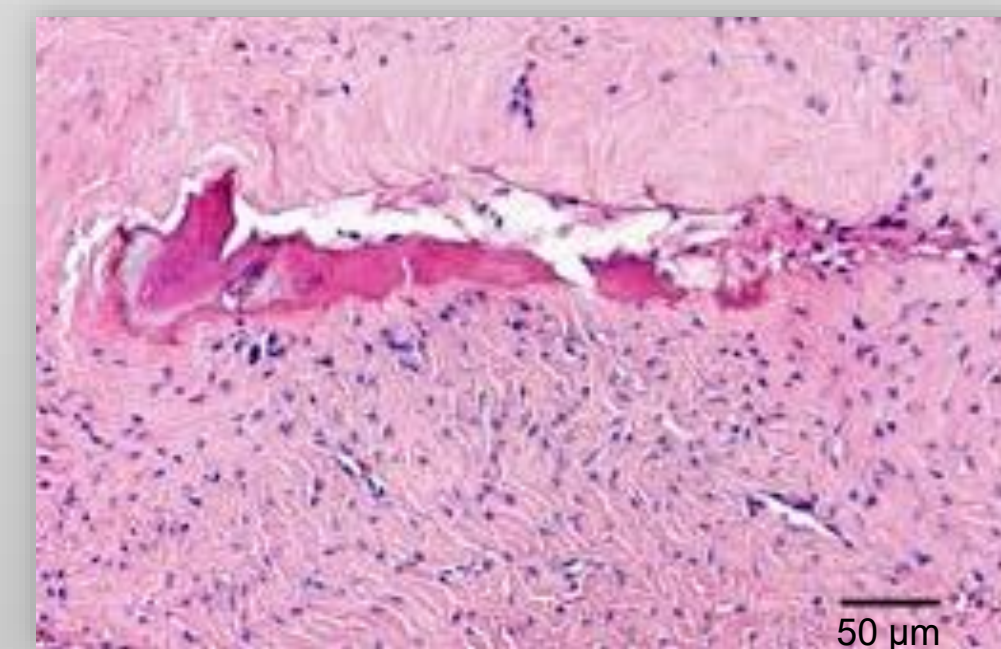


CT, transversal plane; Metrics of the cyst

Histopathology



Cyst lumen; The lumen is lined by a cuboidal to cylindrical, non-ciliated epithelium (single-layered to multi-layered)



Cyst wall; The cyst wall contains scarce fibrocytes with abundant collagen fibers with occasional osseous metaplasia.

Discussion and Conclusion

Etiopathogenesis

- | | |
|---------------------------------|--|
| Primary or secondary cyst | - primary: no communication with adjacent structures (lacrimal system, sinus, nasal cavity...) |
| Epithelial cyst or dermoid cyst | - epithelial cyst: no adnexal structures (hair, sebaceous or sweat glands...) |
| Dysontogenetic or posttraumatic | - dysontogenetic: no history of trauma or surgery |
| Original tissue | - gland, glandular excretory duct or nasolacrimal duct: cuboidal to cylindrical epithelium |

The described entity is likely to be a dysontogenetic orbital cyst. Etiopathogenesis remains unclear, however tissue derivation of the cyst from the lacrimal drainage system appears plausible.

Literature

- HÅKANSSON, Nils Wallin; HÅKANSSON, Berit Wallin. Transfrontal orbitotomy in the dog: an adaptable three-step approach to the orbit. *Veterinary ophthalmology*, 2010, 13(6), 377-83.
- HARIDY, Mohie, et al. Coenurus cerebralis cyst in the orbit of a ewe: research communication. *Onderstepoort Journal of Veterinary Research*, 2014, 81(19), 1-4.
- HOLMBERG, Bradford J., et al. Taenia coenurus in the orbit of a chinchilla. *Veterinary ophthalmology*, 2007, 10(1), 53-9.
- ITO, Kanako, et al. Periorbital cyst with bone defect in a dog. *Journal of veterinary medical science*, 2006, 68(7), 747-8.
- MUNOZ, E., et al. Retrobulbar dermoid cyst in a horse: a case report. *Veterinary ophthalmology*, 2007, 10(6), 394-7.
- O'REILLY, Anu, et al. Taenia serialis causing exophthalmos in a pet rabbit. *Veterinary ophthalmology*, 2002, 5(3), 227-30.
- REGNIER, Alain; RAYMOND-LETRON, Isabelle; PEIFFER, Robert L. Congenital orbital cysts of neural tissue in two dogs. *Veterinary ophthalmology*, 2008, 11(2), 91-8.
- Saunders Comprehensive Veterinary Dictionary, 3 ed. 2007 Elsevier.
- SHIELDS, Jerry A.; SHIELDS, Carol L. Orbital cysts of childhood—classification, clinical features, and management. *Survey of ophthalmology*, 2004, 49(3), 281-99.
- STUCKEY, Jane Ashley; MILLER, William W.; ALMOND, Gregory T. Use of a sclerosing agent (1% polidocanol) to treat an orbital mucocele in a dog. *Veterinary ophthalmology*, 2012, 15(3), 188-93.
- WALDE, I., et al. Retrobulbar dermoid cyst in a Dachshund. *Veterinary & Comparative Ophthalmology*, 1997, 7(4), 239-44.